

Neck Ultrasound

Amy Kule, MD

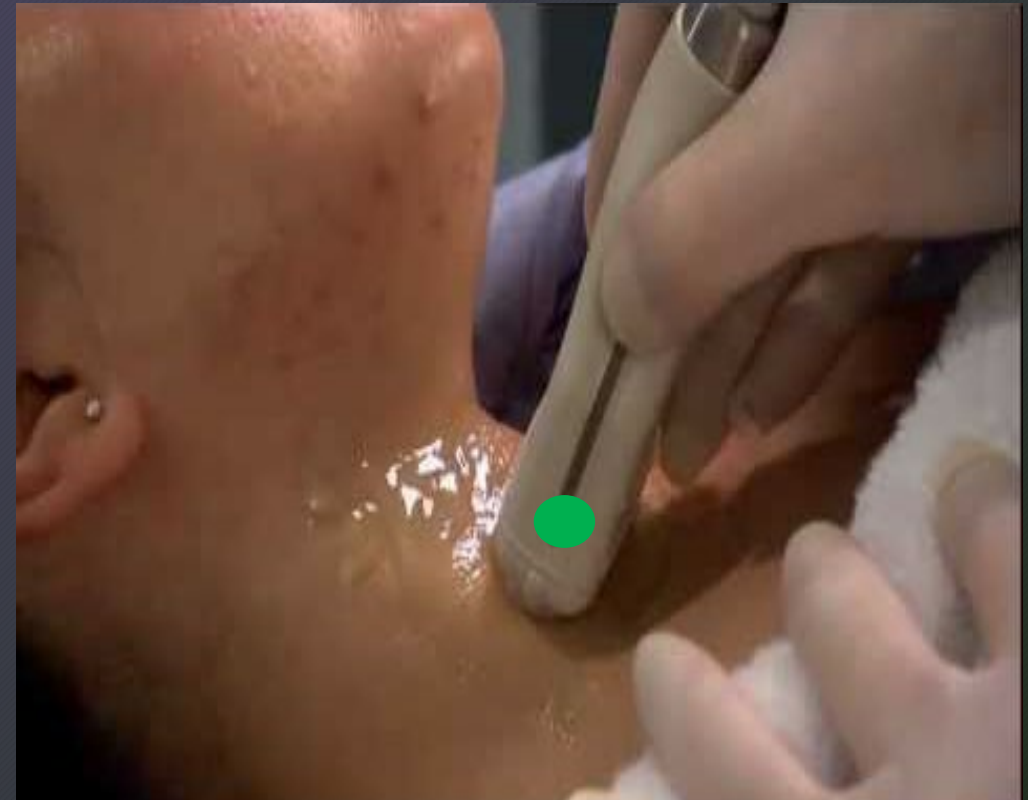Director, Vertically Integrated Curriculum for Point of Care Ultrasound
Department of Emergency Medicine

Getting Started

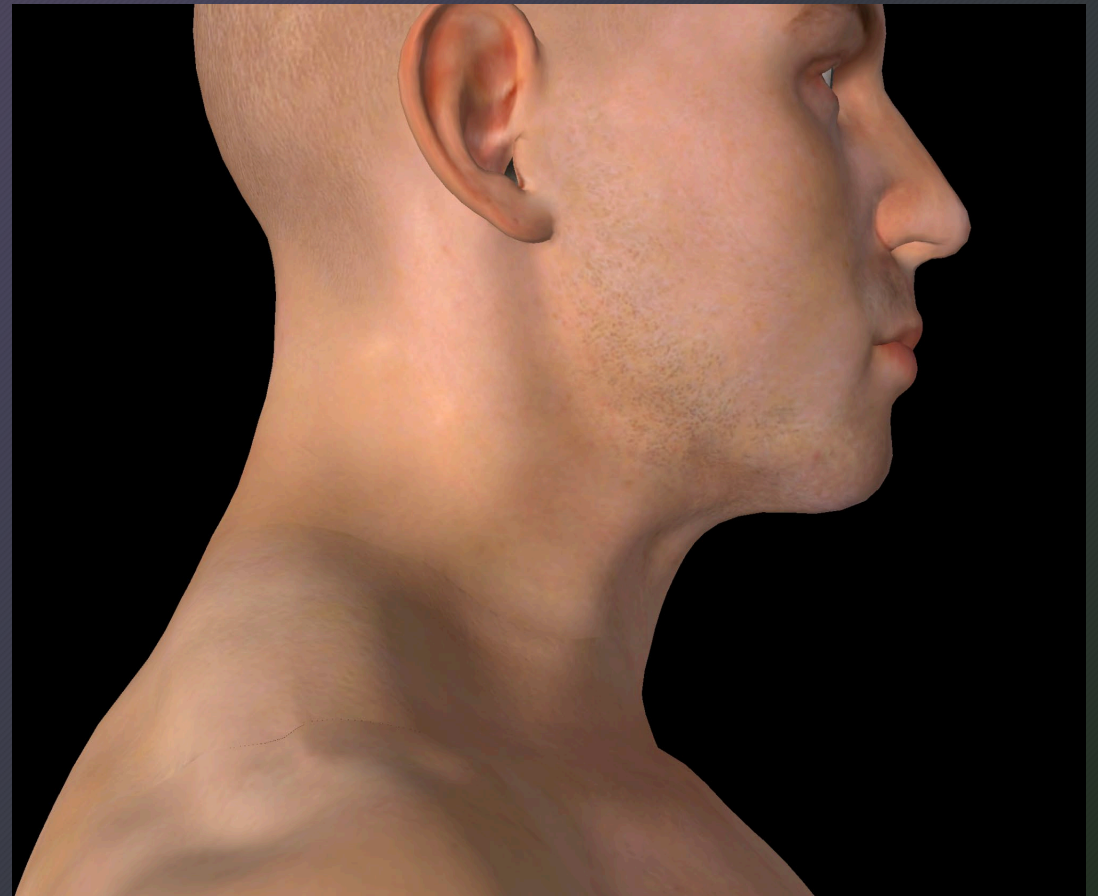- What anatomic structure is being scanned?
- Which probe should be used?
- Where should the probe be placed?
- Does depth need to be adjusted?
- Does gain need to be adjusted?

Neck Scanning Protocol

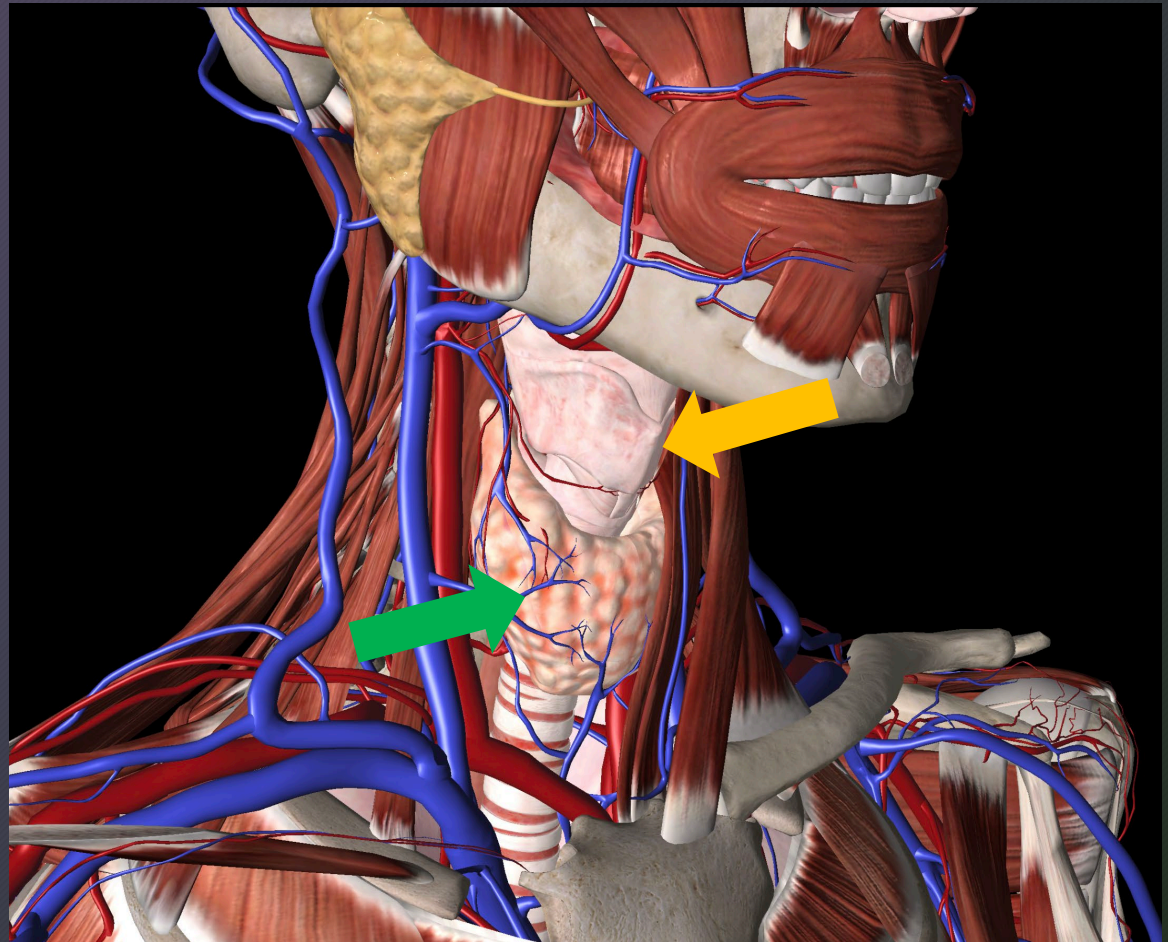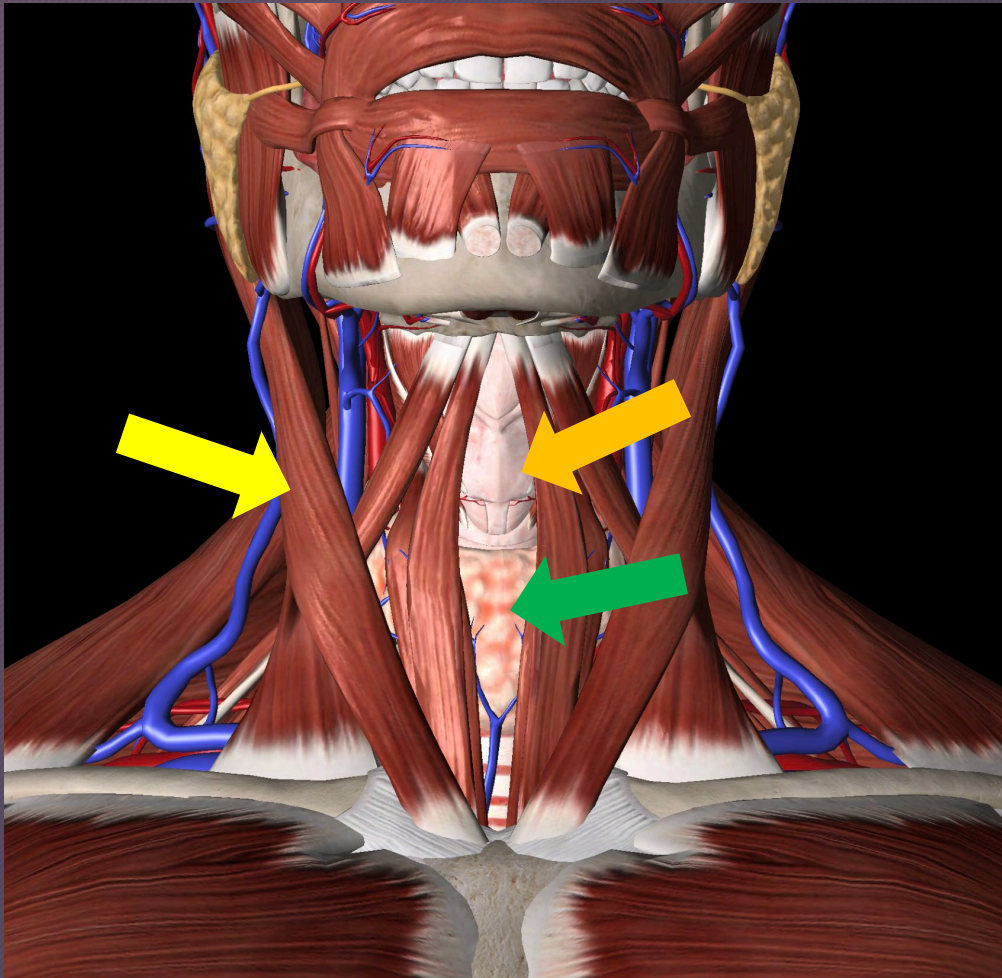
- Patient Positioning
 - Supine (Anterior neck)
 - Head turned to the opposite side (Lateral neck)
- Probe Selection
 - Linear
- Technique
 - Transverse plane



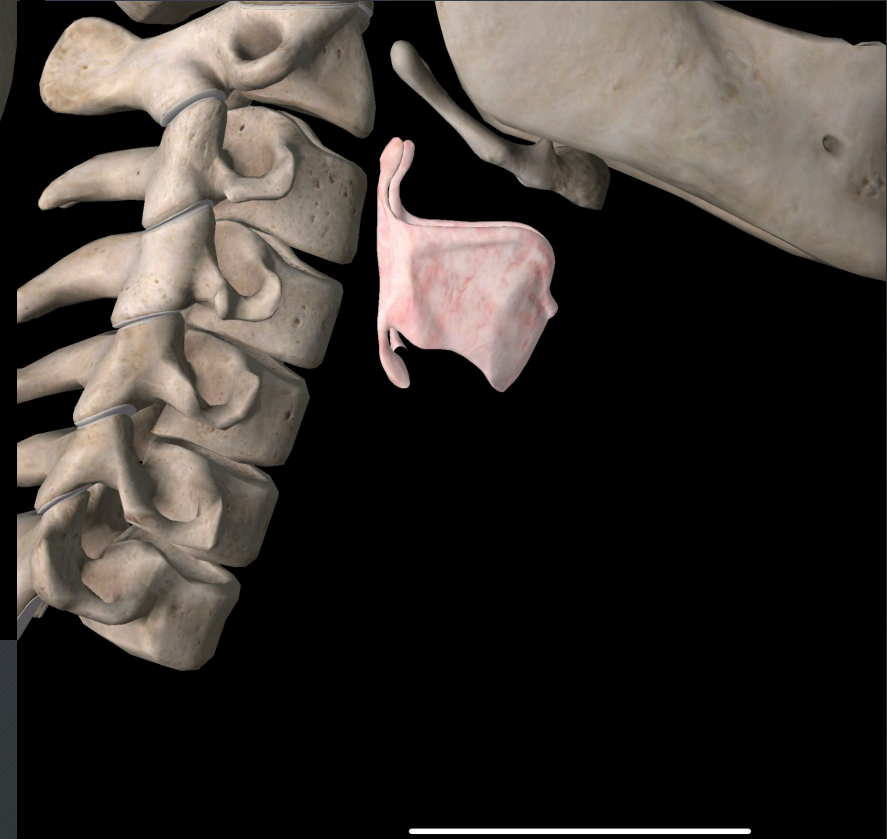
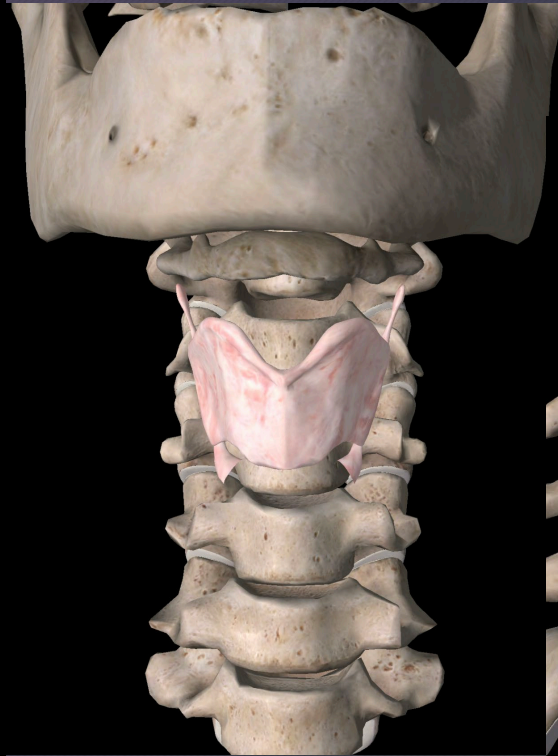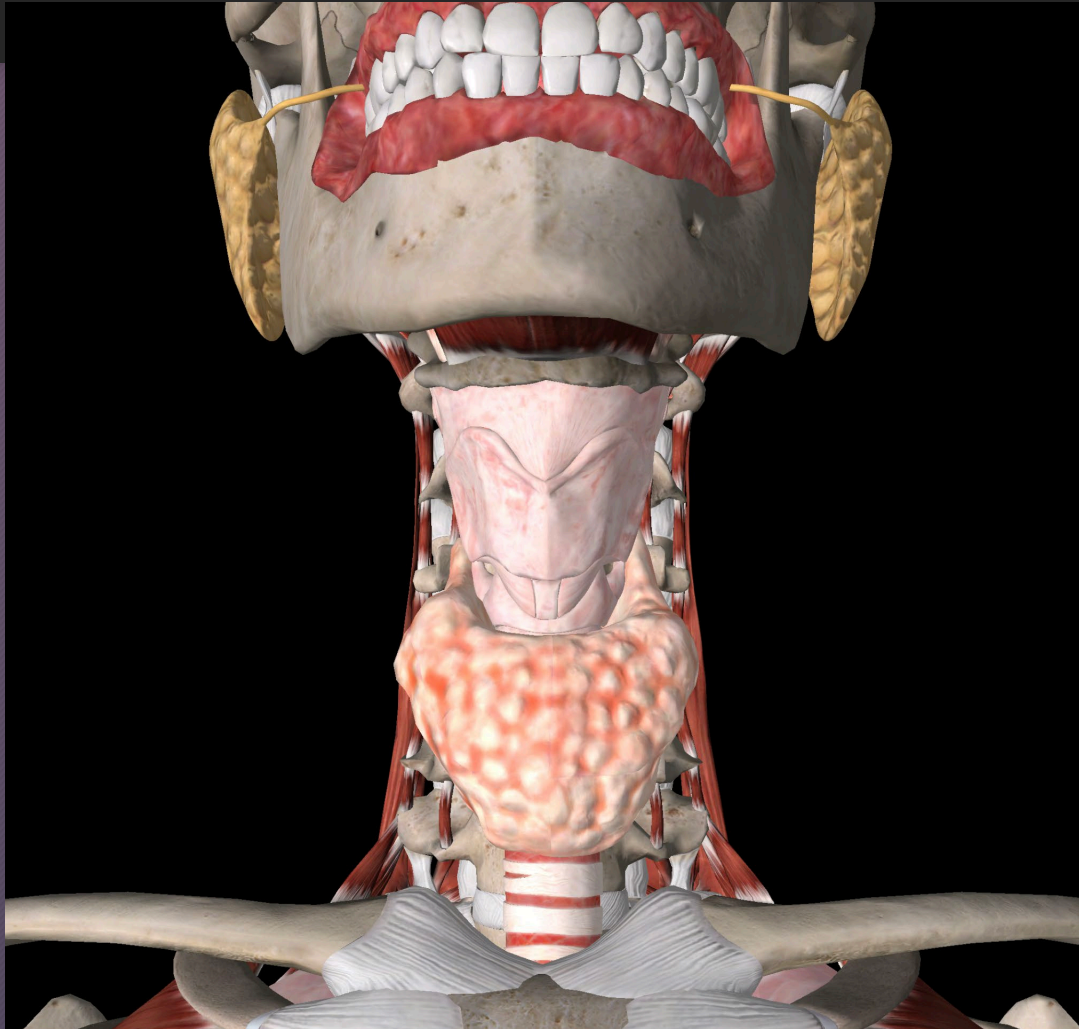Anatomy Refresher



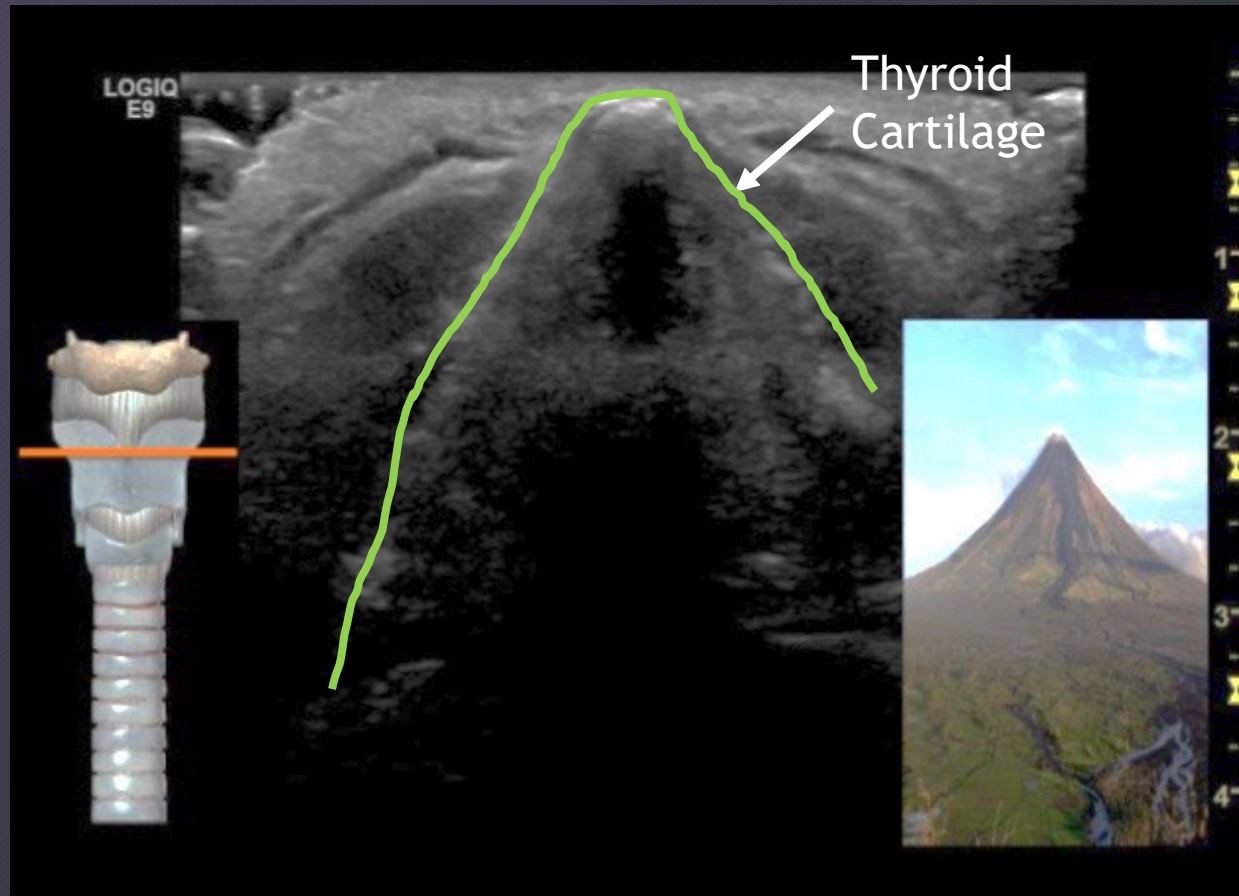
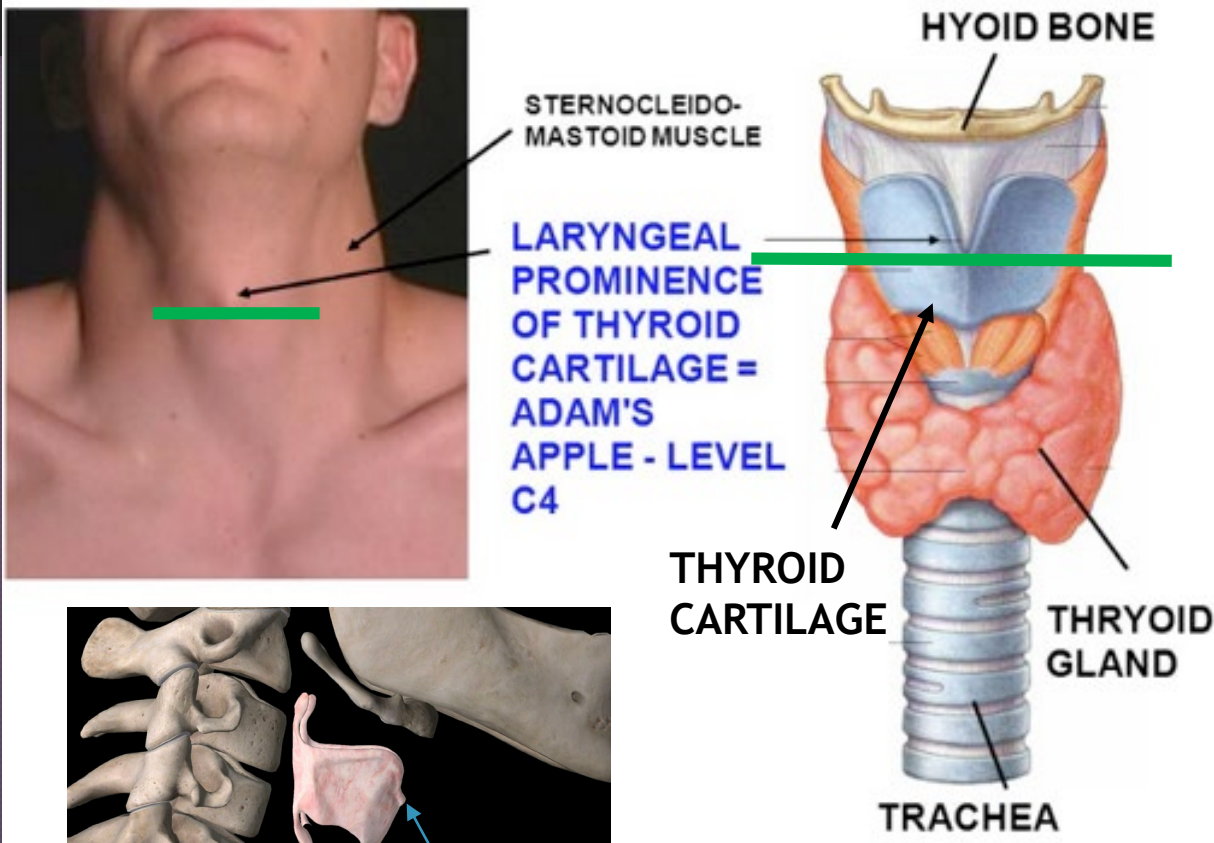
Anatomy Refresher



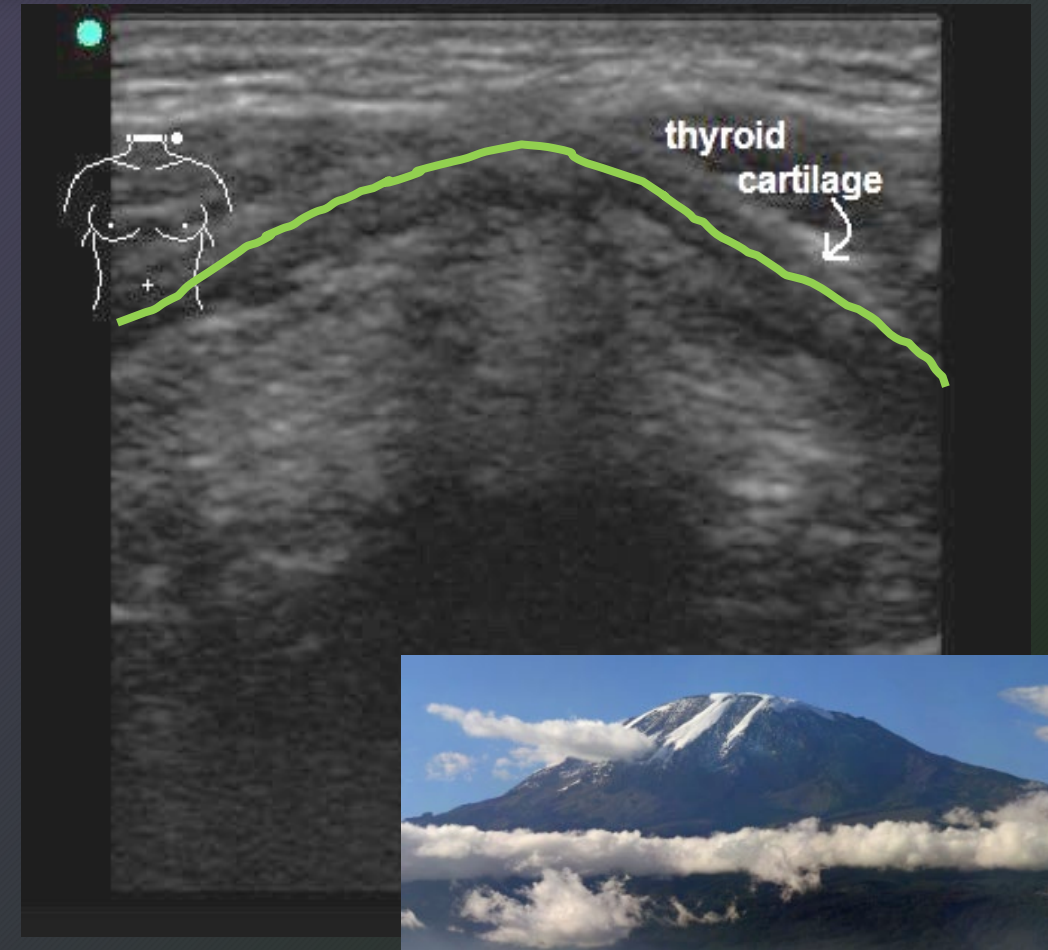
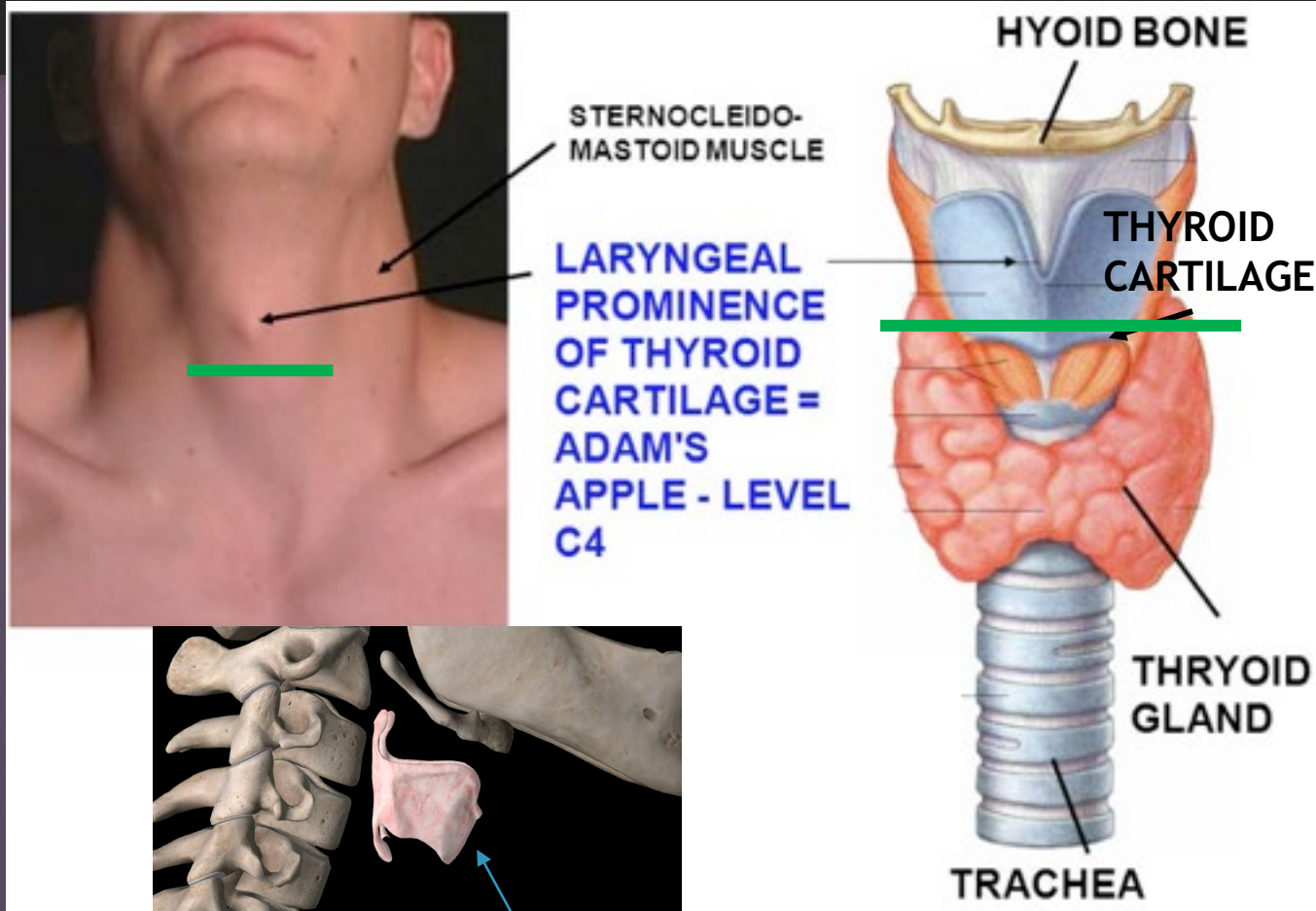
Anatomy Refresher - Thyroid Cartilage



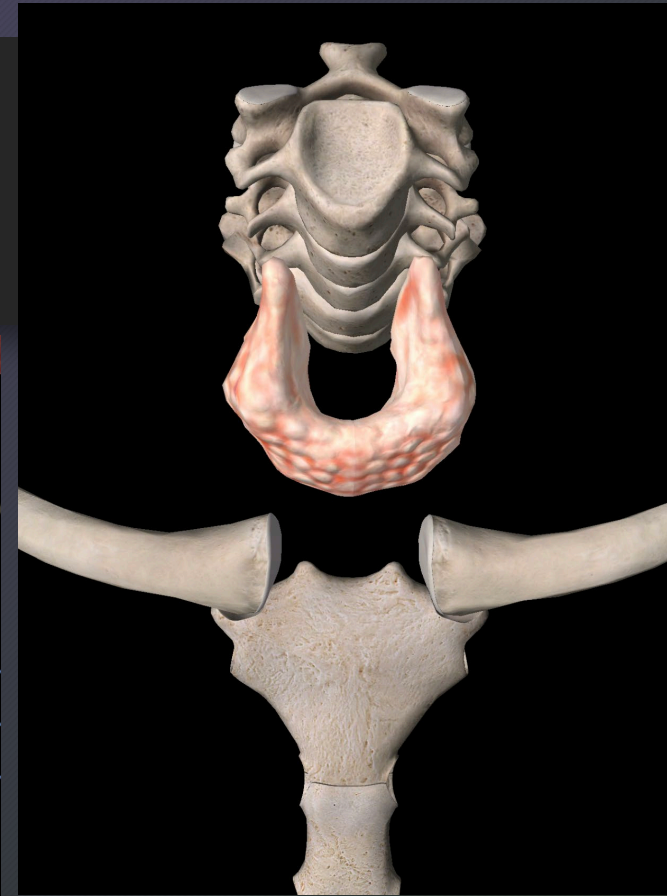
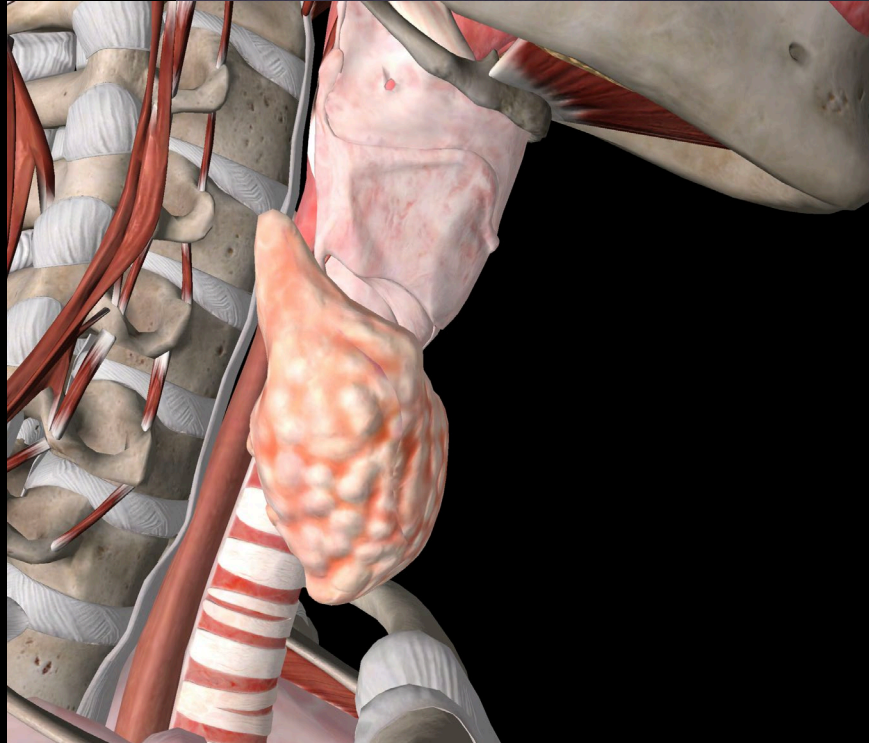
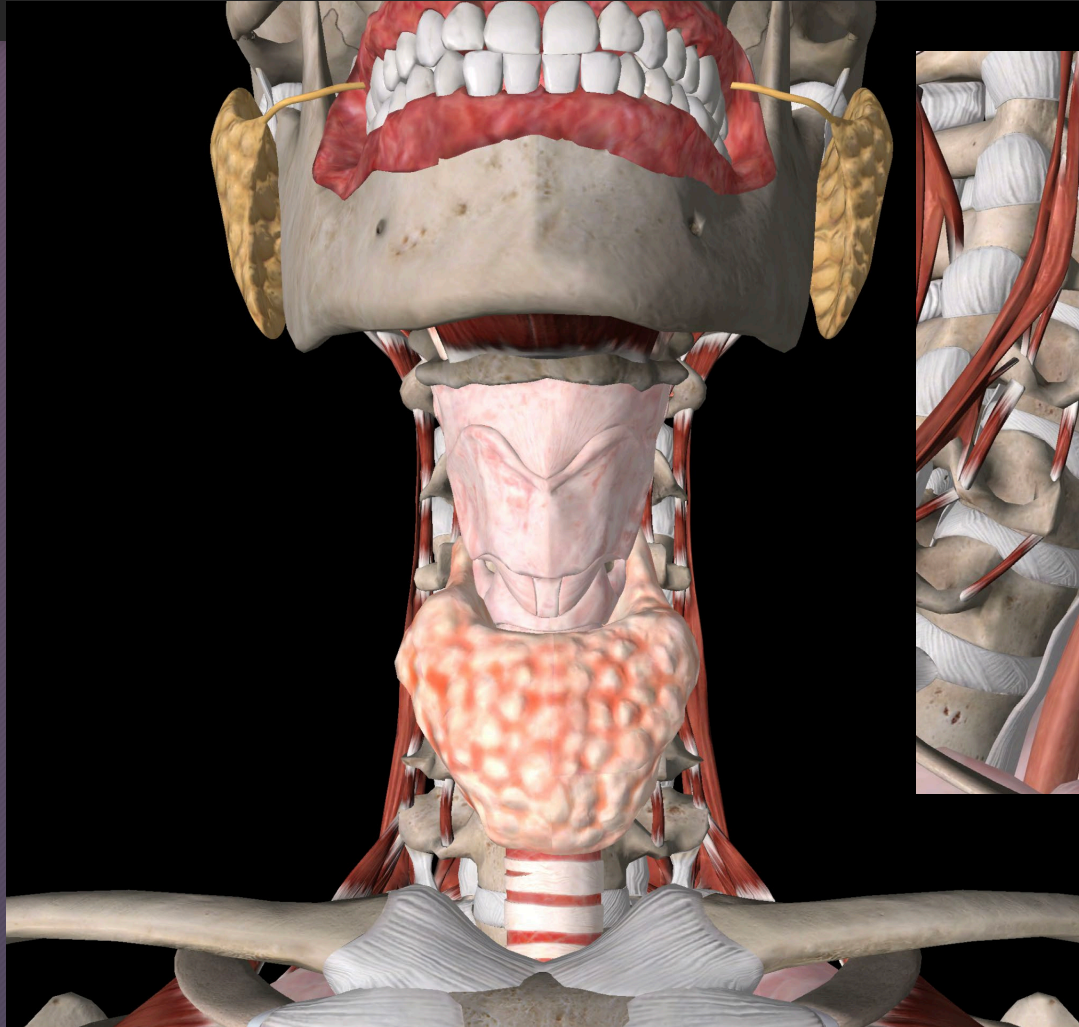Anatomic Landmarks - Laryngeal Prominence



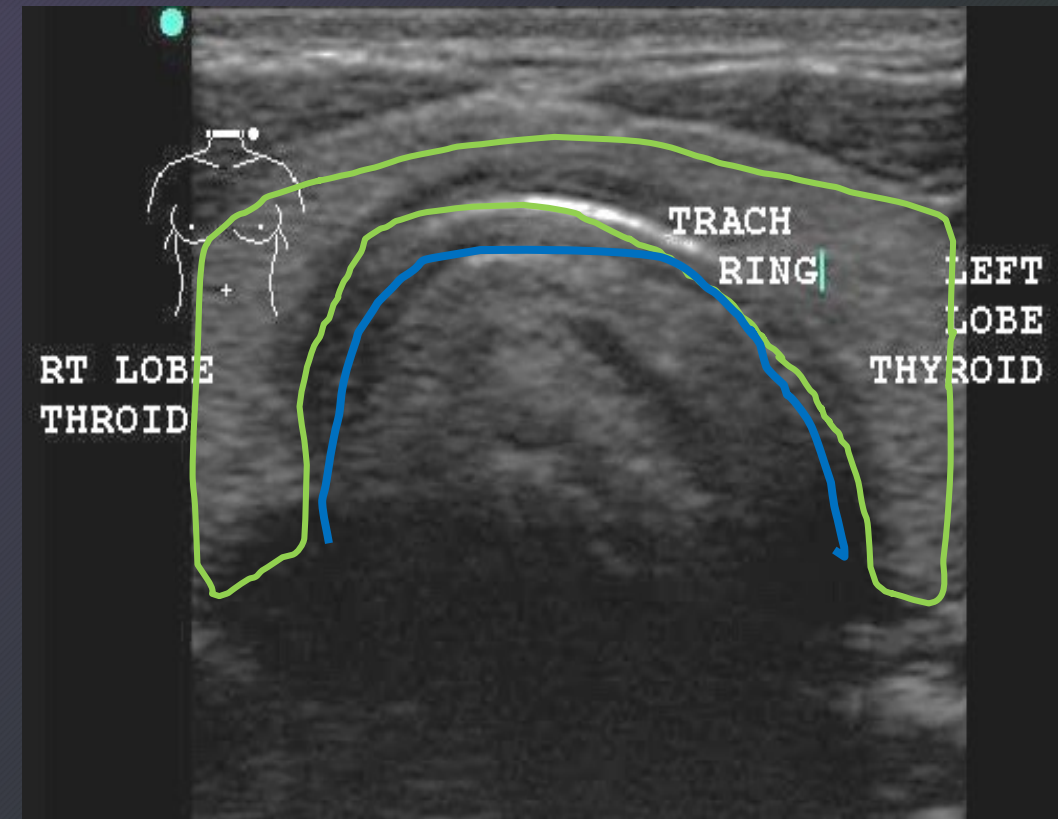
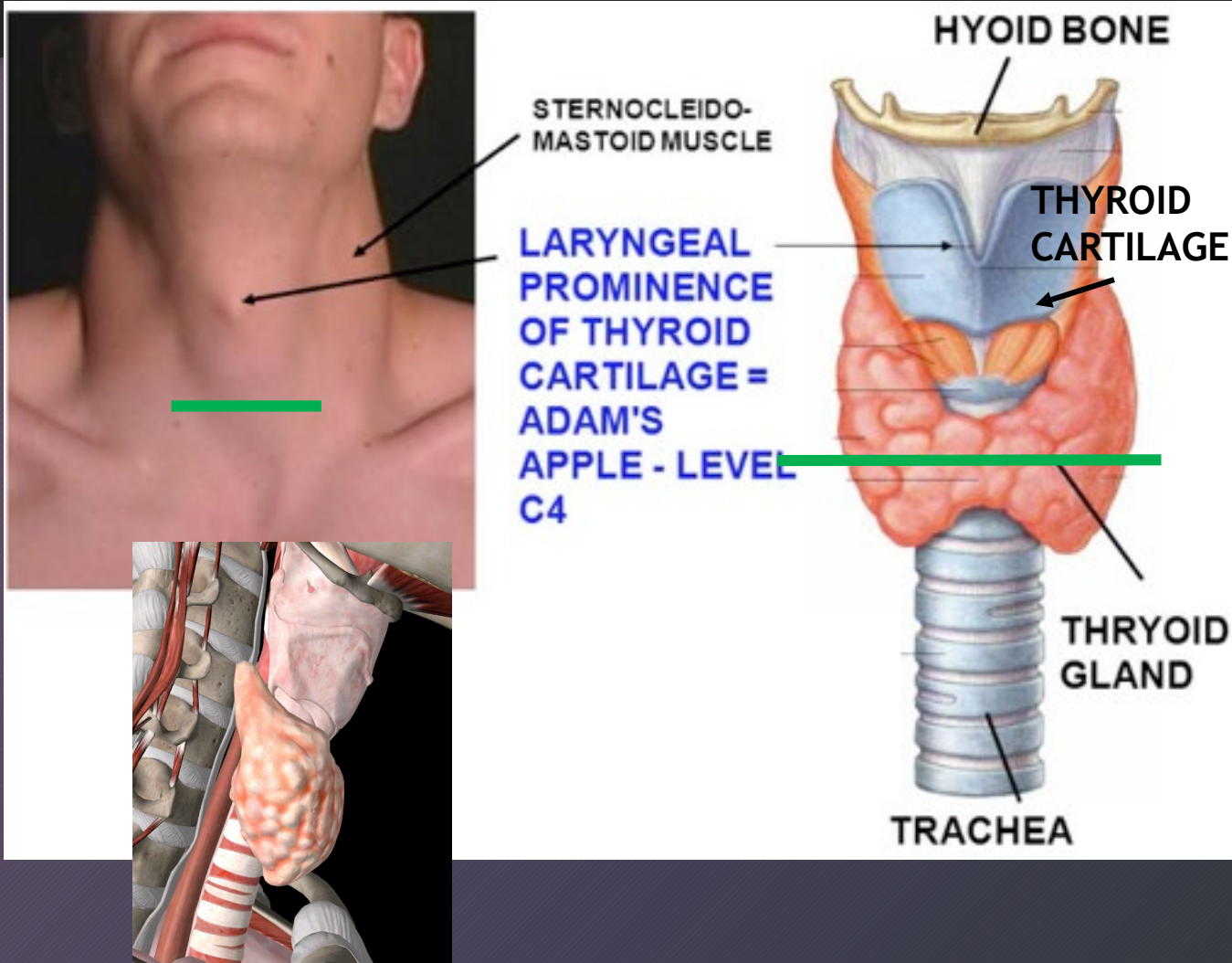
Anatomic Landmarks



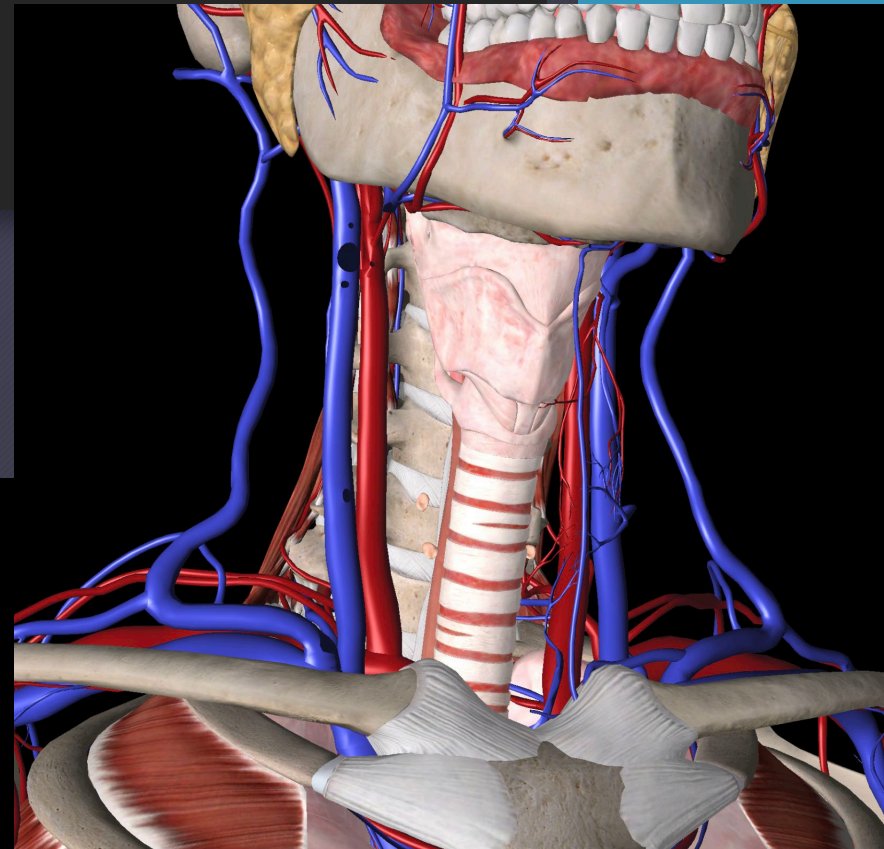
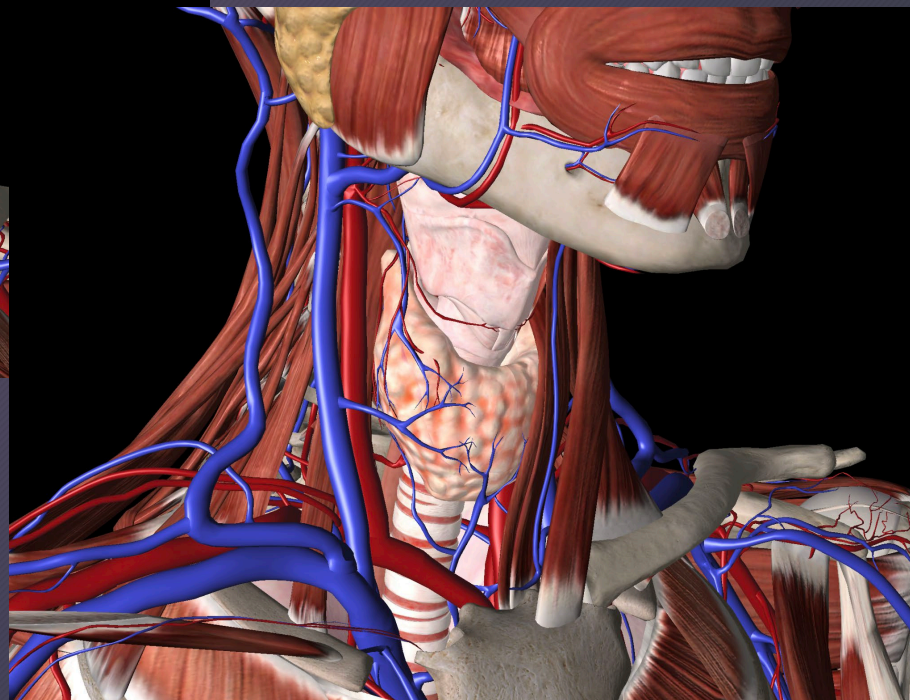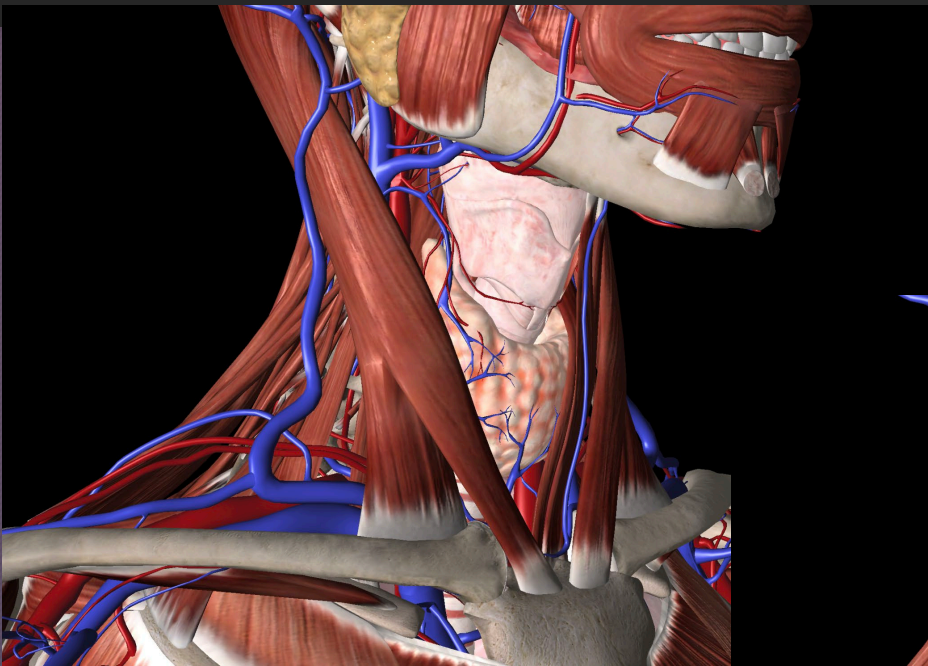Anatomy Refresher - Thyroid



Anatomic Landmarks



Anatomy Refresher - Lateral Neck



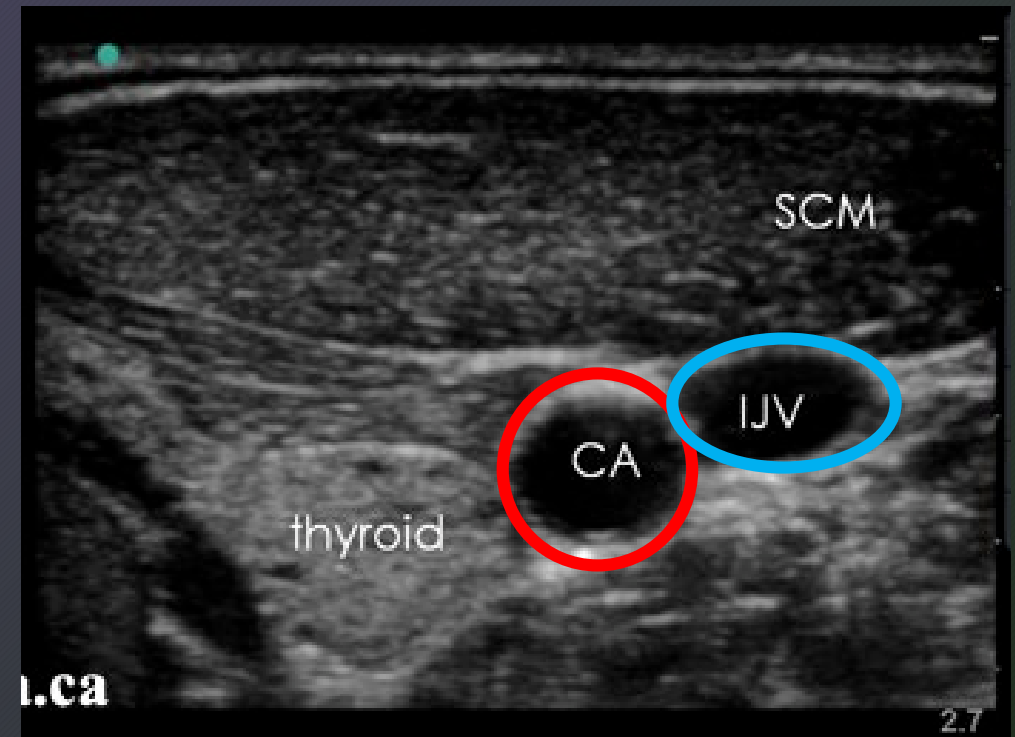
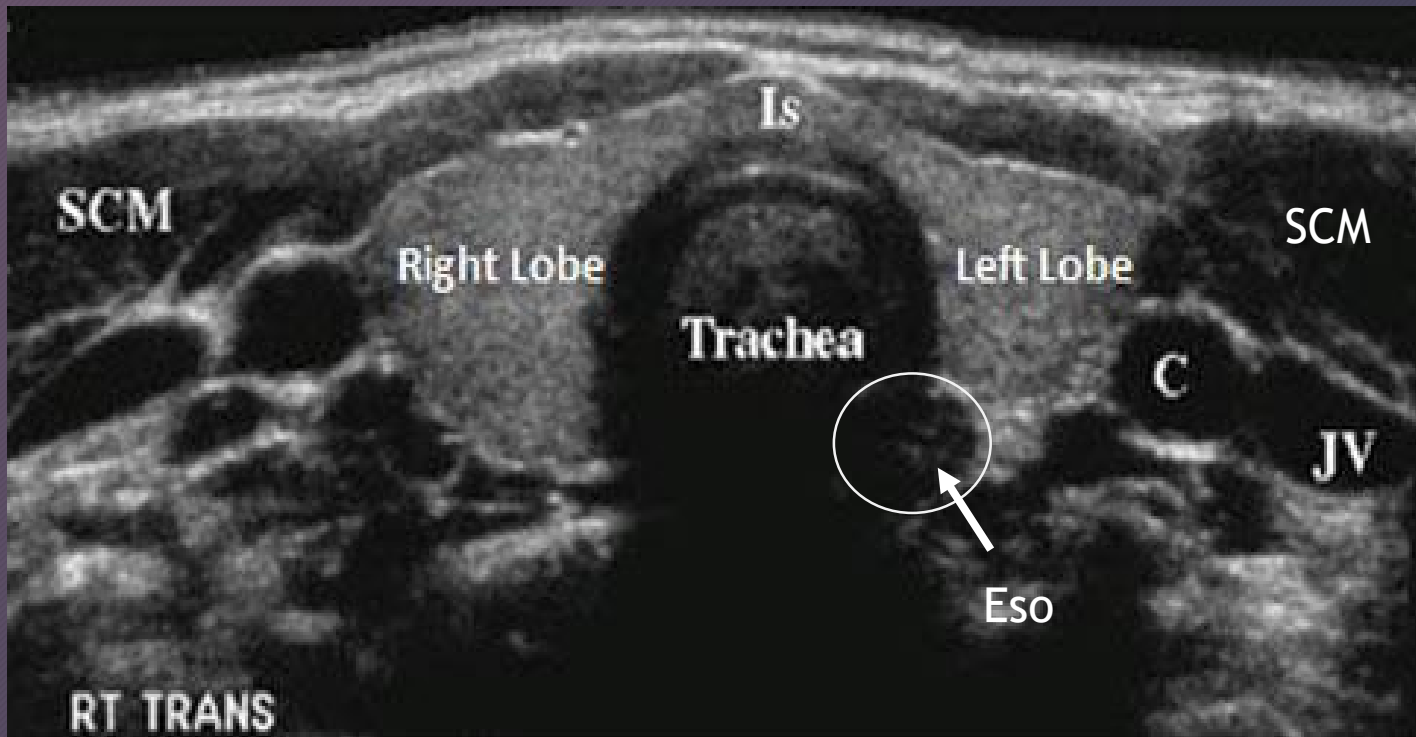


Overview of Lateral Neck Structures

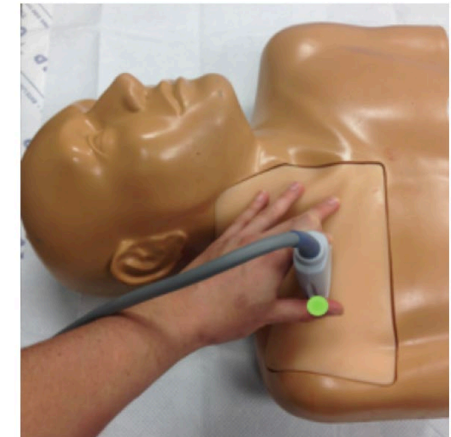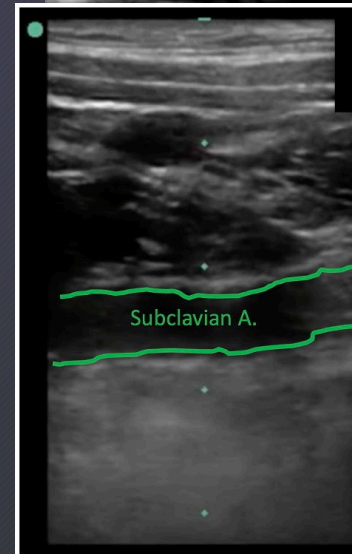
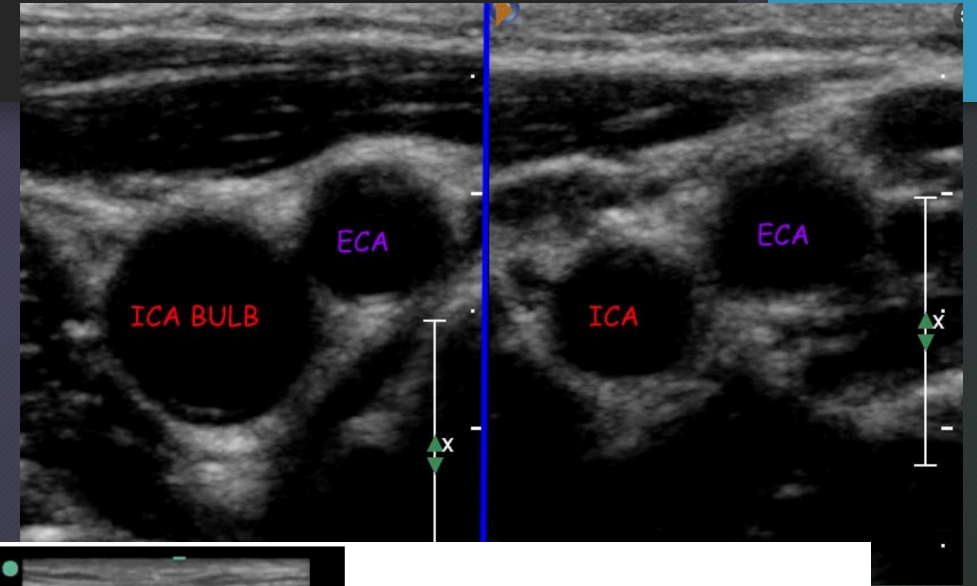
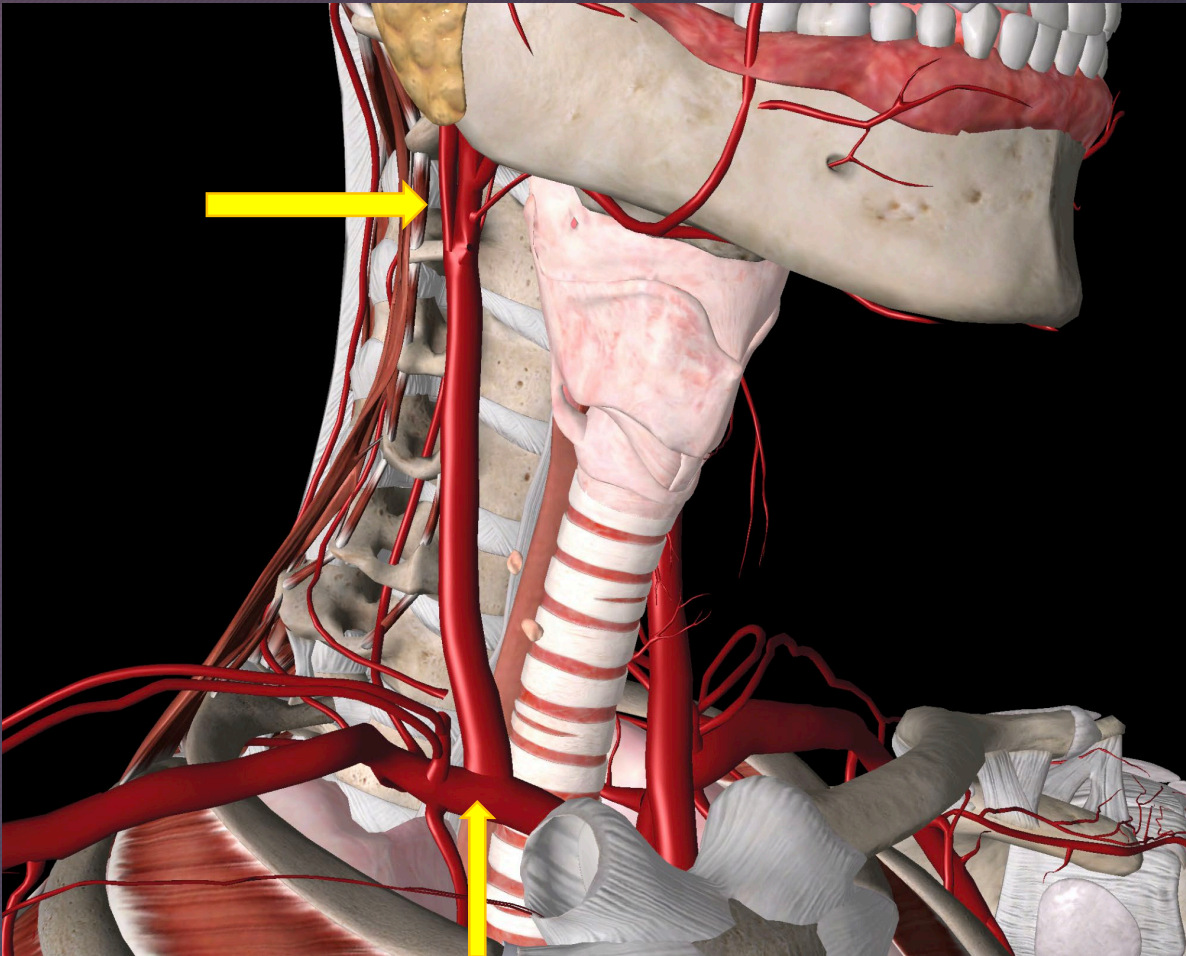
Right

Middle

Left



Anatomic Refresher - Carotid Branches



Questions?

Akule@lumc.edu